



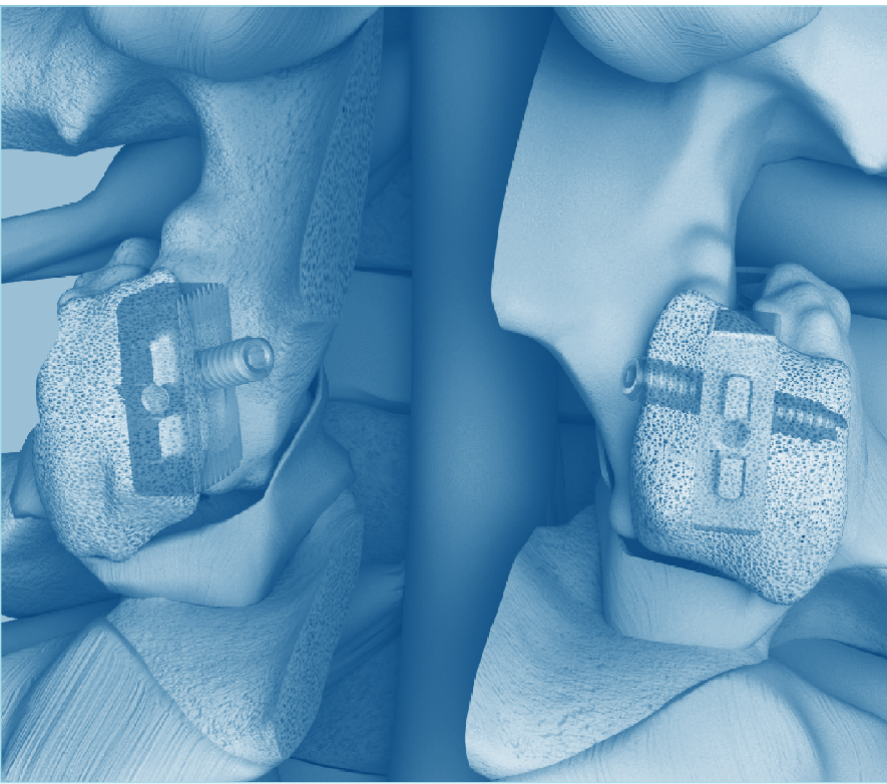
Fixation of Lumbar Facet Joint

FFX[®]

Facet FiXation Device

ICD-10 Coordination and Maintenance Committee Meeting

March 2024





Ahmed M. Khan, MD

Central Connecticut Neurosurgery and Spine
Assistant Clinical Professor
Neurological Surgery University of Connecticut School of Medicine
Chief of Neurosurgery, The Hospital of Central Connecticut,
New Britain, Connecticut

Education and Training:

Undergraduate Degree: Cornell University - magna cum laude
Medical School: University of Connecticut School of Medicine
Neurosurgery Residency: Rhode Island Hospital

Dr. Khan is board certified by the American Board of Neurological Surgery and a member of the North American Spine Society, Congress of Neurological Surgeons, and the American Association of Neurological Surgeons. He has been practicing neurosurgery for over 20 years and implements the latest techniques in stereotactic, robotic and minimally invasive neurosurgery.

Disclosure: Dr. Khan is a paid consultant for SC MEDICA.

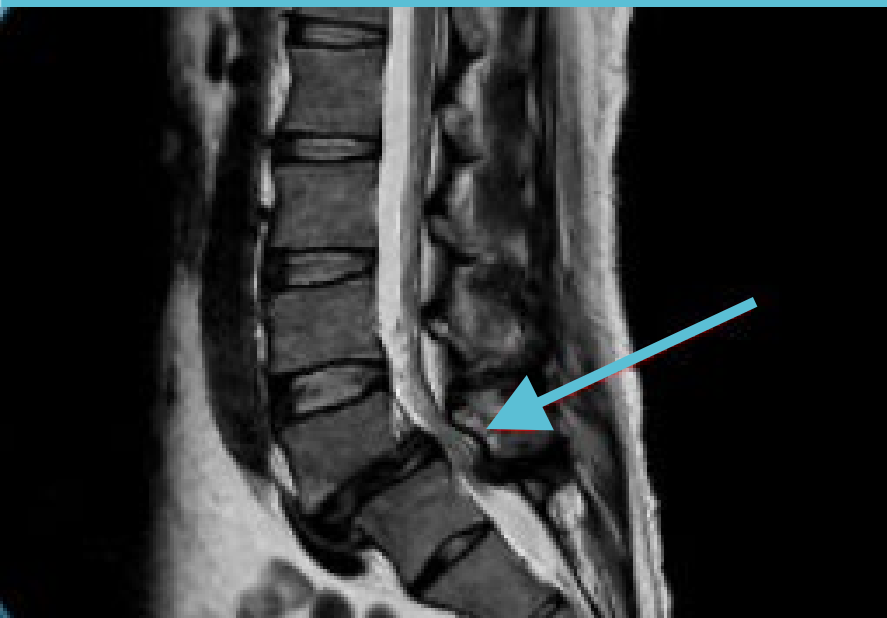On This Call



Camille Srour, PhD

Founder & Chief Executive Officer
SC MEDICA
Strasbourg, France

- ▶ Lumbar spinal stenosis (LSS) occurs when spaces in the spine narrow and creates pressure on the spinal cord & nerve roots.
- ▶ Typically affects older individuals who have multiple comorbidities – prevalence is increasing.
- ▶ Initially treated medically, then with surgical decompression alone or with fusion with pedicle screw constructs.



Clinical Need

Current Standard: Pedicle Screws for Lumbar Fusion



Pedicle screw constructs can result in adjacent level degeneration due to the rigidity produced.

25%

Of patients undergoing fusion with pedicle screw constructs experience post-fusion instability at the adjacent vertebral level to the one initially treated.

10%

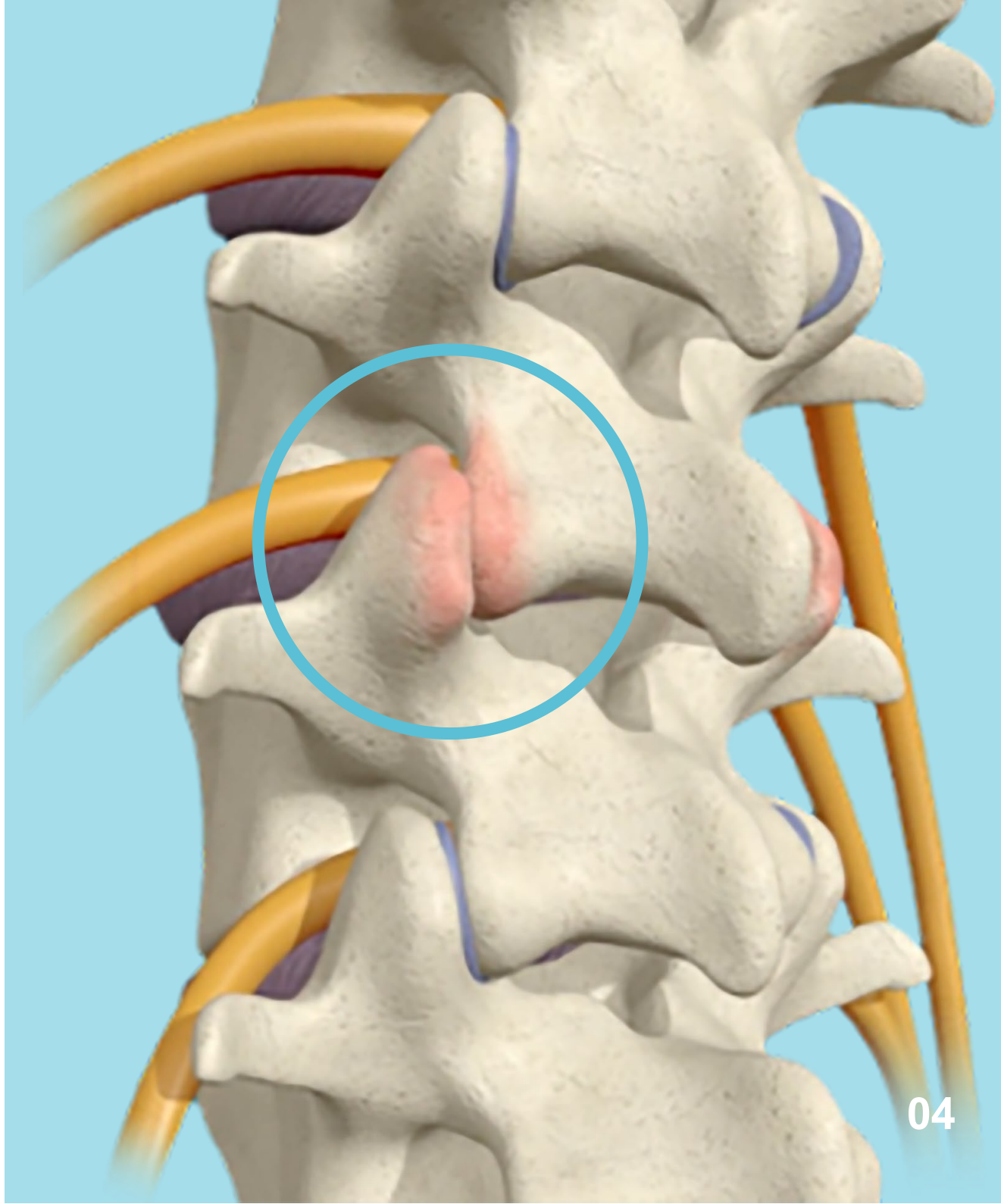
Reoperation rate resulting from failed lumbar fusion and/or persistent back pain.



Potential for significant blood loss and soft tissue damage during pedicle screw placement procedure.

Role of the Facet Joint in LSS

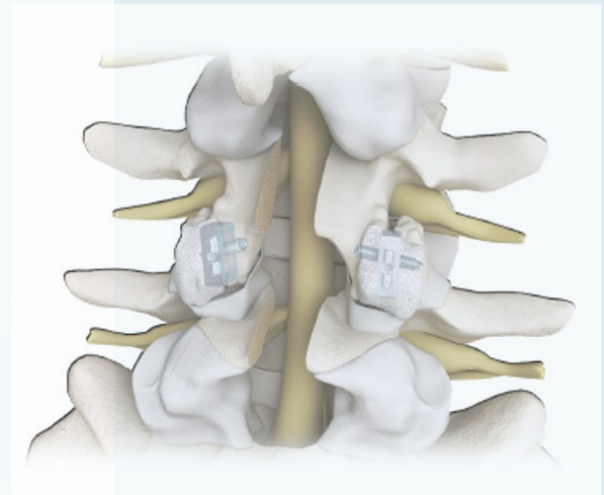

- ▶ Lumbar facet joints degenerate over time contributing to the development of lumbar spinal stenosis (LSS).
- ▶ Facet syndrome is root cause of back pain for up to 45% of patients.
- ▶ Procedures which address facet degeneration have been shown to reduce pain associated with LSS.



FFX®

Device designed to fit tightly and is press fit into the facet joint space. Accompanying facet screw compresses the joint. Tight implant with compression leads to better bone growth and higher fusion rate.

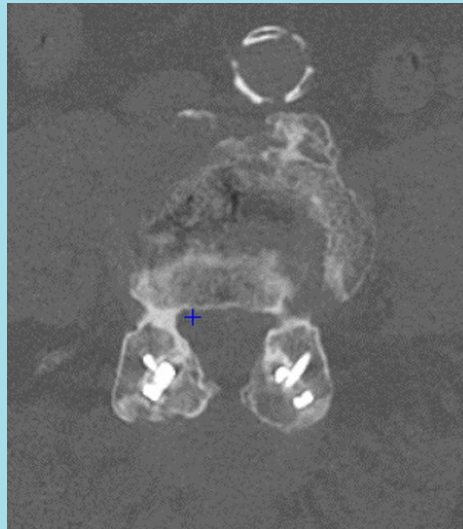- ▶ The FFX implant is designed to prevent spinal instability and facet motion by enabling lumbar facet joint fusion following surgery to treat lumbar spinal stenosis and facet syndrome.
- ▶ Sterile, single use, long-term implantable device made of titanium.
- ▶ Available in 6 different sizes to ensure proper fit.
- ▶ Two devices placed bilaterally per level.
- ▶ A facet screw is placed in conjunction with each implant.
- ▶ Autologous graft material is placed inside and posterior to the implant.



Regulatory Status

Indication for Use:

The FFX system is indication for use in patients with lumbar spinal stenosis or facet syndrome. The device is intended to be used with autologous graft material to achieve lumbar fusion through immobilization of the lumbar facet joints.



FFX devices implanted bilaterally between the facet joints in conjunction with facet screws placement.

2017

Received CE Mark in November


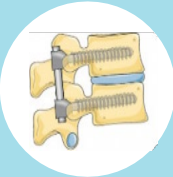



2021

Received FDA Breakthrough Device Designation in October

2023

510(k) submission in August

FFX A Unique Device and Procedure

Device		Implantation location and trajectory	Facilitates fusion via rasping of the facets to expose spongy bone?	Increases foraminal height?	Press-fit effect on the facets?	Facet compression?
FFX system (cage + facet screw)		<ul style="list-style-type: none"> Inserted in the facet joint plane (cage) + Transfacet/transcage (facet screw) 	Yes	Yes	Yes	Yes
Pedicle screws		<ul style="list-style-type: none"> Inserted into the spinal pedicle and vertebral body with attachment of connecting rods 	No	No	No	No
Interspinous devices		<ul style="list-style-type: none"> Inserted interspinous / interlaminar 	No	Yes	No	No
Facet screws		<ul style="list-style-type: none"> Translaminar approach, or Transfacet pedicle 	No	No	No	Yes
Facet dowels		<ul style="list-style-type: none"> Inserted in the facet joint plane 	No	No	Yes	No

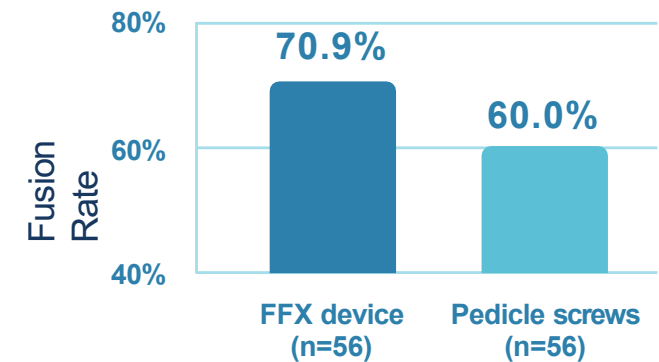
Clinical Results

FFX vs. Pedicle Screws

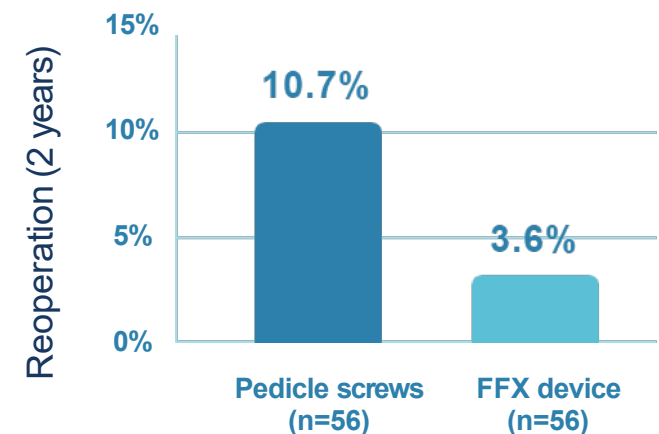
Criteria for fusion:

- ▶ Bridging bone between the facet joints for both the left and right sides for all levels undergoing fixation.
- ▶ $\leq 3\text{mm}$ translational motion between vertebrae on flexion/extension via CT-scan.
- ▶ Range of motion (ROM) $\leq 5^\circ$.
- ▶ No evidence of lucency ($\leq 25\%$) surrounding the device.

Improved Fusion Rate



Less Reoperations



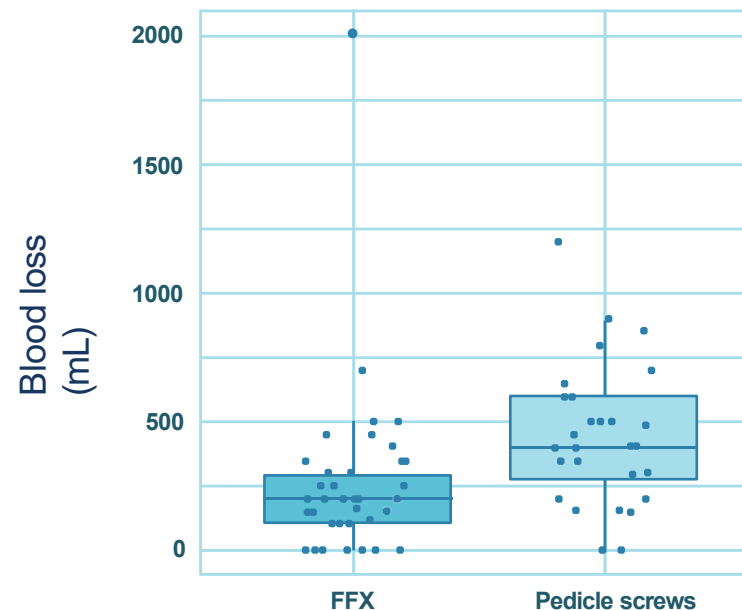
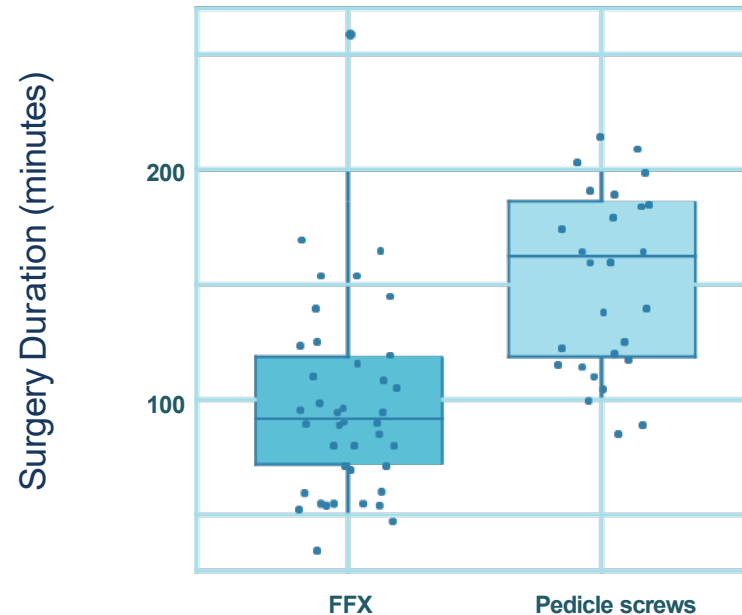
Reduced Operative Time and Blood Loss

- ▶ Mean operative time was significantly longer for the Pedicle screw group versus the FFX group (152.5 ± 39.4 vs. 99.4 ± 44.0 minutes; $p < 0.001$).
- ▶ Mean operative blood loss was significantly greater for the Pedicle screw group versus the FFX group (446.5 ± 272.0 vs. 251.0 ± 315.9 mL; $p < 0.01$).
- ▶ Differences were independent of the number of levels operated on.

Procedure documented in the OR

POTENTIAL ADVERSE EVENTS AND POSSIBLE COMPLICATIONS

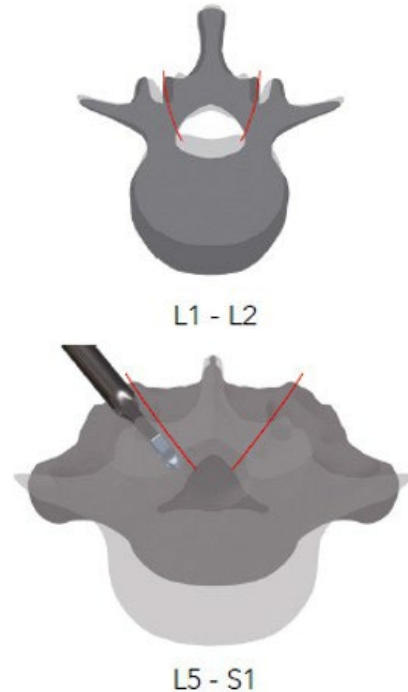
- Early or late-onset infections, haematoma, allergies, cutaneous necrosis
- Necrosis of bone or bone resorption, pseudarthrosis, chondrolysis, algodystrophy, bone resorption or fractures, consolidation delays
- Mechanical complications (implant failure or migration, wear, loosening, etc.), implant fracture
- Neurological complications (clinical or electrical monitoring is advised: wake-up test), pain
- Cardiovascular disorders, thrombosis



Surgical Technique

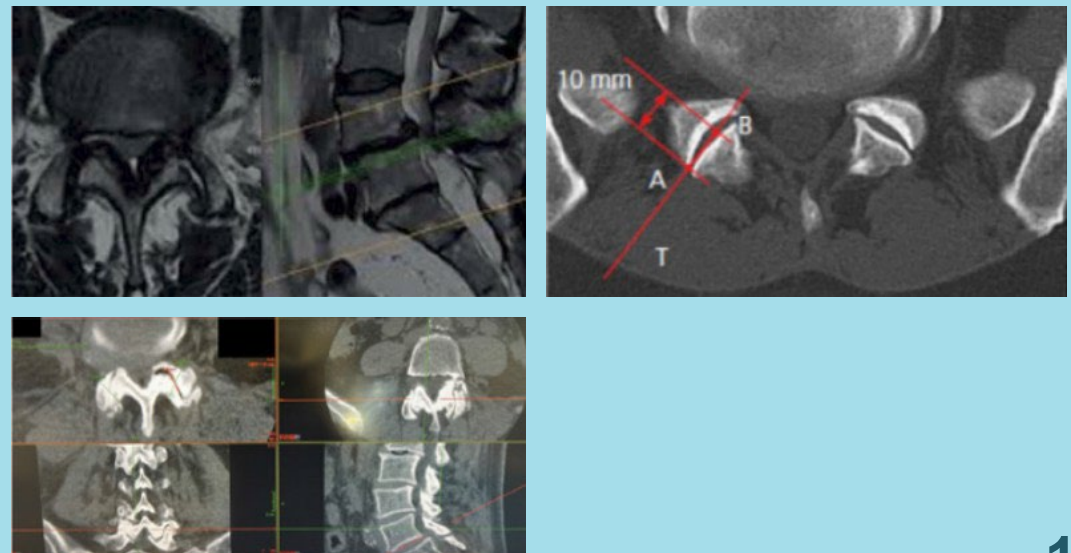
1. Preoperative imaging

The orientation of the facet joints varies depending on the level to be instrumented.



2. Surgical planning

- Identify the facet joint and joint space entrance on axial images. This will guide you in choosing the size of the **FFX** cage.
- Visualize the level of the procedure in transverse view to assess the orientation of the facet joint and shape, as well as obstructive structures (osteophytes, pelvis...).
- To define the correct trajectory (T) of the **FFX** cages and instruments, identify the entrance to the facet joint (A) and the joint space to a depth of 10 mm (B) on axial images (CT or MRI).
- The 10 mm length is the length of the **FFX** cage inserted into the facet joint.



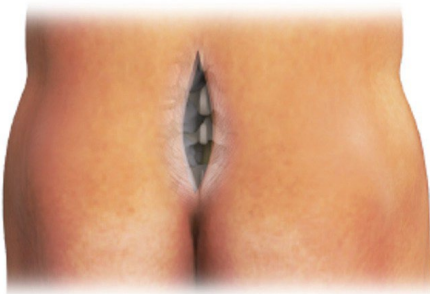Surgical Technique

3. Position and approach

FFX cages are designed to be inserted through a standard posterior approach to the spine. The patient is placed in the genupectoral or ventral decubitus position.

4. Incision

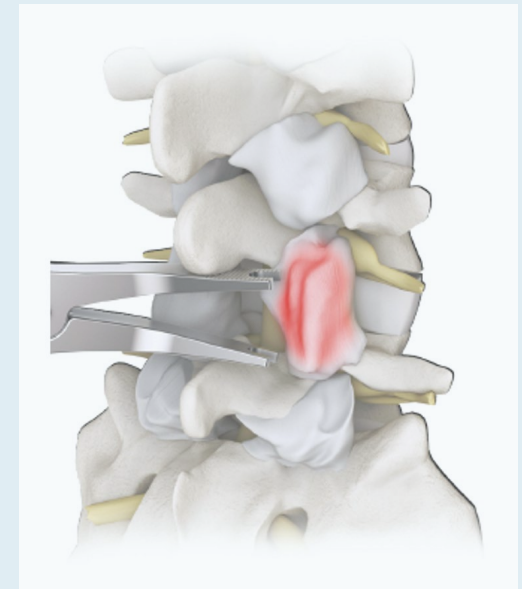
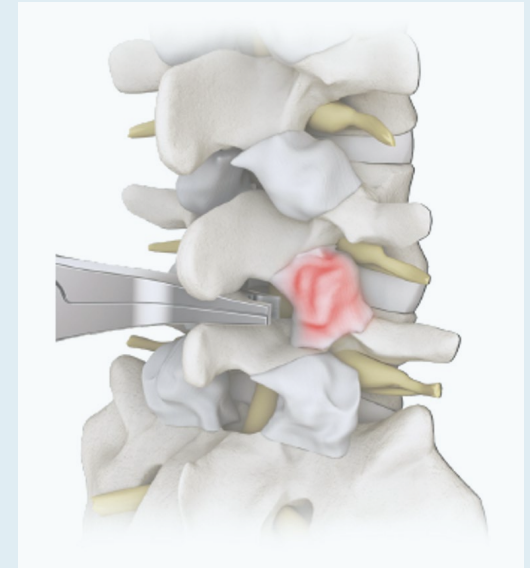
Make a middle sagittal incision with respect to the lumbar canal narrowness after fluoroscopic check.



5. Tracking the articular line

Perform an intermyolamar detachment and locate the facet joints, left and right. Mobilize the segment with the interlamar distractor to visually identify the facet joint space, left and right. The shearing motion of the distractor will help identify the facet joint space.

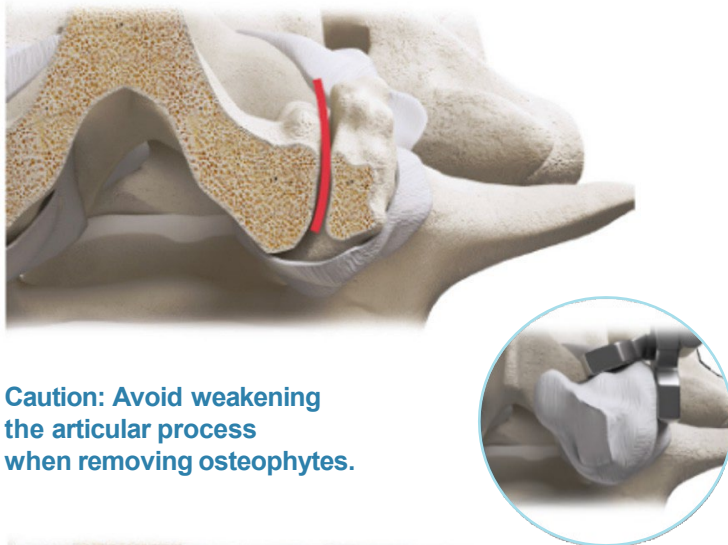
Tip: Place the interlamar distractor as close to the yellow ligament as possible to avoid breakage of the spinous processes.



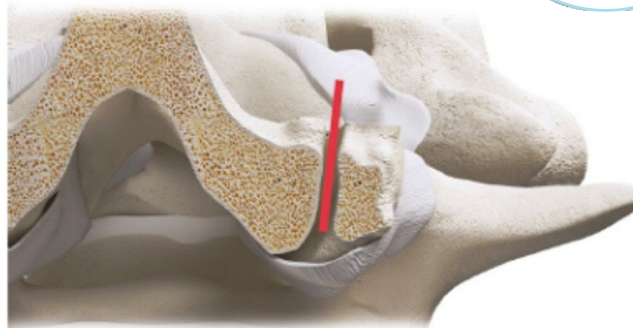
6. Resection of osteophytes

Uncap and remove osteophytes with Gouge forceps.

This step will help identify the actual articular line and help make it straighter, in accordance with the shape of the **FFX** cage.



Caution: Avoid weakening the articular process when removing osteophytes.



Surgical Technique (2)


7. Preparation of the facet joint

Open the facet joint space with the chisel.

Revive the facet space with the rasp until cancellous bone is reached.

This step prepares for a future successful fusion of the joint.

Important: After using the rasp, use the curette to remove residual cartilage in the joint space and optimize the chances of fusion.



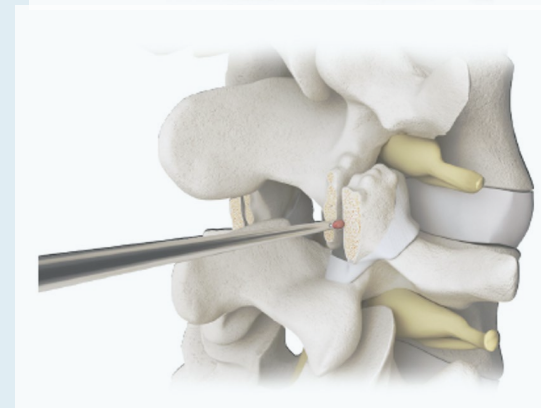
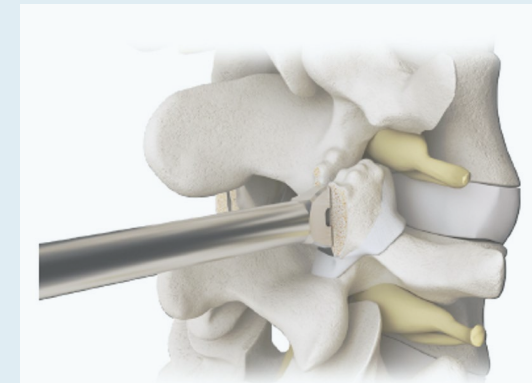
Facet chisel
57.002.00T



Rasp
57.003.00T



Curette
57.006.24



Surgical Technique (3)

8. Choice of FFX cages

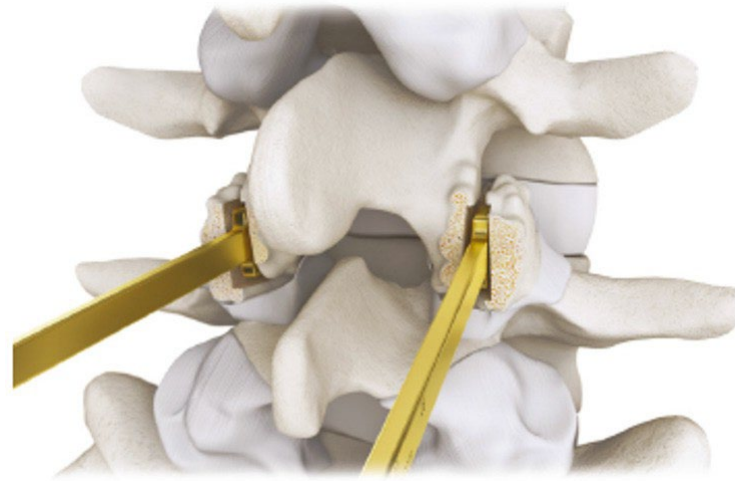
Insert the narrowest trial implant (C=2.5 mm, gold color), simultaneously into the left and right facets. Simultaneous insertion ensures that the facet on the opposite side is not closed.

If the trial size does not sufficiently grip in the joint space, repeat the trial with the thicker model (C=3mm, green color).

Select the **FFX** cage with the same thickness as the trial implant tested.

If none provided sufficient grip, select the **FFX** cage with the maximum thickness (C=3.5mm).

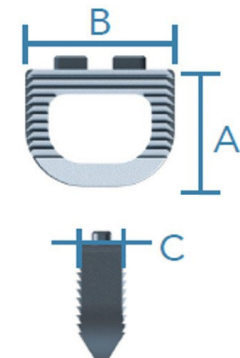
The **FFX** cage width is chosen by comparison with the trial implants, all of which were B=11mm wide. If this width seems insufficient, select a wider **FFX** cage (B=13mm).



Trial implant FFX 11 × 2.5
TRIAL- 57.000.10




Trial implant FFX 11x3
TRIAL- 57.000.30



Reminder: There are three FFX cage thicknesses (C=2.5mm, 3mm, 3.5mm), two widths (B=11mm, 13mm) and only one depth (A=10mm), corresponding to a choice from a total of 6 references.

Surgical Technique (4)



Graft holder
57.004.00



Implant holder
57.001.30N

Use two implant holders, two FFX cages per level.

9. Graft insertion

Mount the **FFX** cage on the implant holder. Place the **FFX** cage on the autologous graft material holder.

Insert the autologous graft material into the cavity of the **FFX** cage.

Surgical Technique (5)

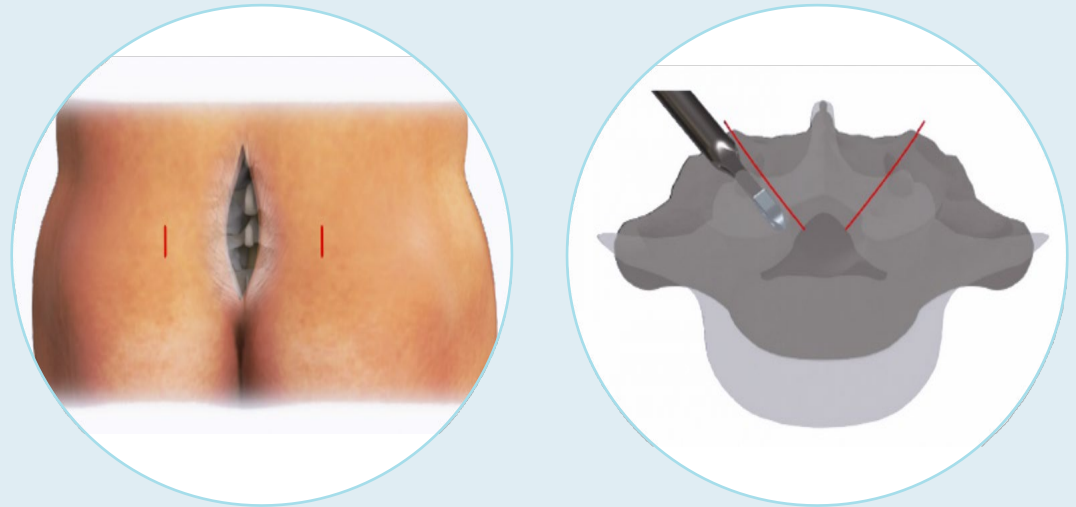
10. Insertion of FFX cages

Simultaneously insert the **FFX** cages mounted on their implant holders halfway into the joint space on the right and left sides.

Remove the implant holders by carefully unscrewing them.

Important:

Simultaneous insertion of FFX cages avoids closure of the facet on the opposite side.

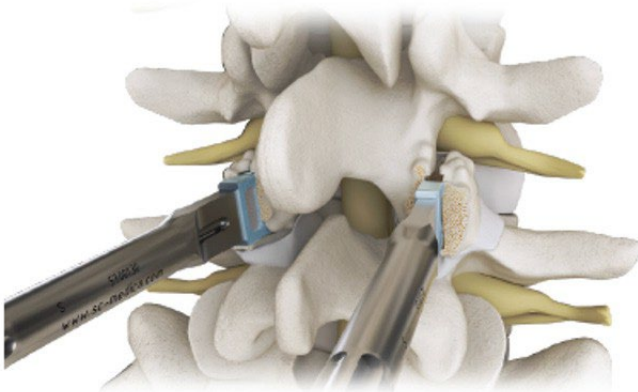


Particularities of the facet orientation of the L5-S1 level:

The orientation of the L5-S1 facet joints is horizontal in the axial plane.

Tip: If necessary, make two lateral counter-incisions to insert FFX cages at the L5-S1 level.

Alternatively, insert FFX cages "bottom-up" (not laterally), orienting the FFX cages along an axis parallel to the spine.



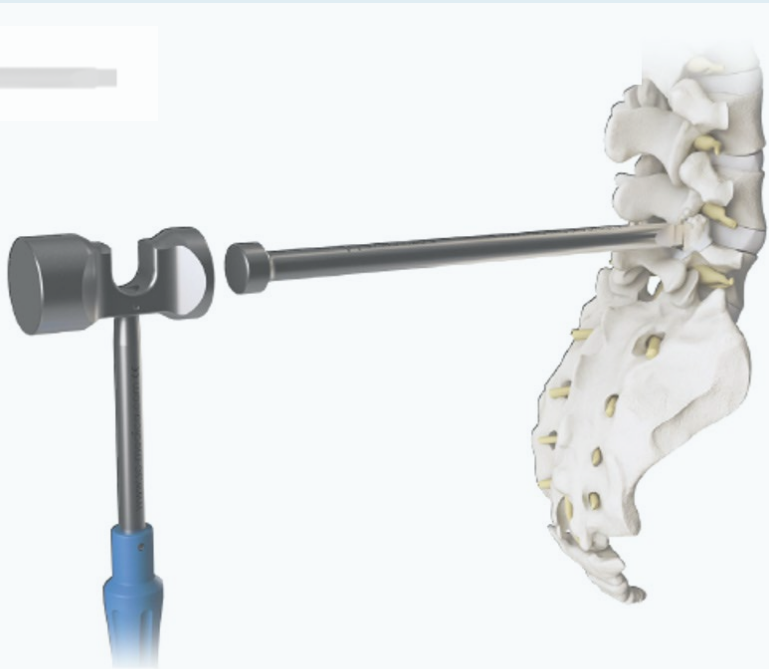Surgical Technique (6)

11. Impaction of FFX cages

With the impactor, push the **FFX** cages up to 2mm below the surface of the articular mass.



Impactor
57.001.20N

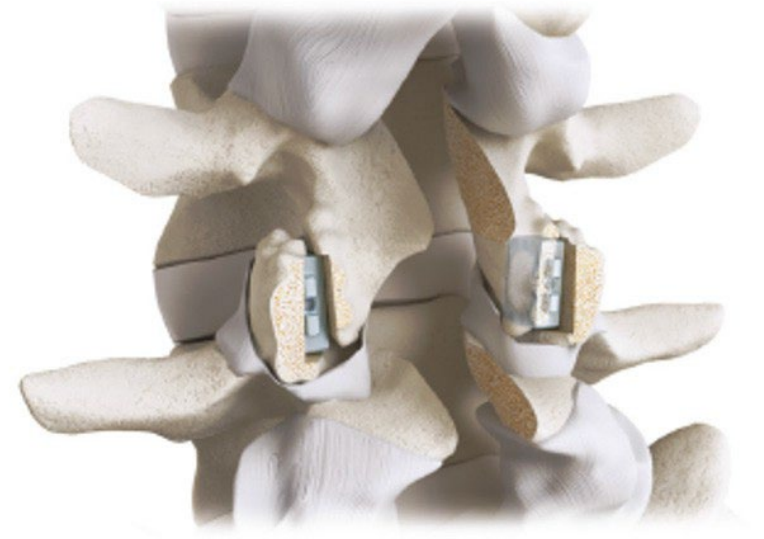


12. Lumbar decompression

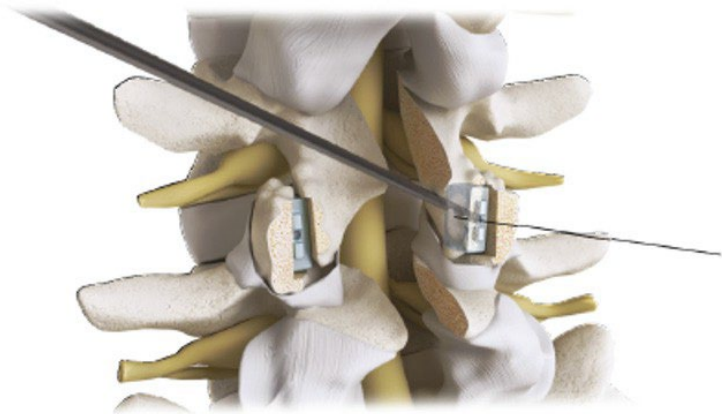
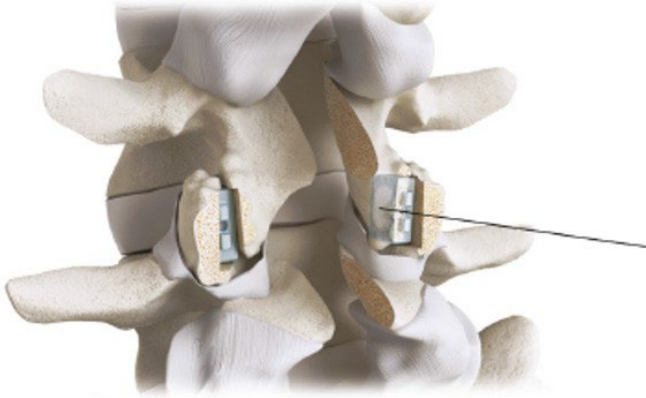
Perform a laminectomy and canal recalibration according to the usual technique.

Important :

Decompression must be performed AFTER the FFX cage placement, in order not to weaken the facet joints before FFX cage placement.



Surgical Technique (7)



Drill bit



13. Preparation for facet screw fixation

In order to ensure the successful insertion of the facet screw, it is recommended to:

1. Insert a pin (or equivalent) into the posterior fixation hole of the **FFX** cage. This will allow visualization of the targeting axis of the facet screw.
2. By projecting the axis of the pin, make a pre-hole in the IN-OUT direction with a bone awl (not provided) on the lower articular facet of the overlying vertebra, aiming at the central part of the **FFX** cage.
3. Using a drill bit, make a hole in the targeting axis. It is recommended to assemble the drill on a small motor with AO adapter to perform this step (drill bit and AO adapter not provided).

Tip:

During drilling, a feeling of crossing the two cortices of the first facet (lower facet of overlying vertebra), the center of the FFX cage (filled with graft) and the first cortical of the second facet (upper facet of underlying vertebra) makes it possible to define the depth of drilling.

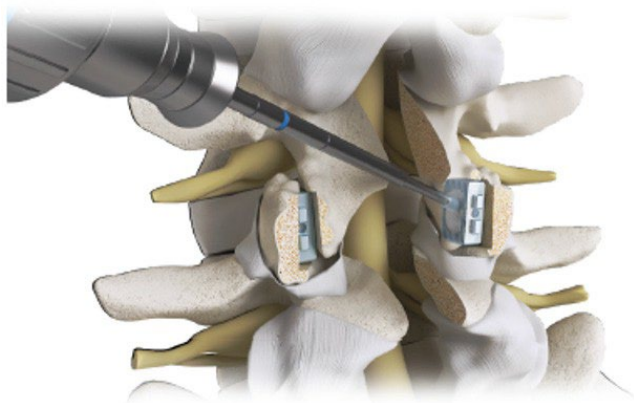
Surgical Technique (8)

14. Insertion of self-compressing facet screw

Insert the self-compressing facet screw with a screwdriver (not supplied) until the screw head is embedded in the articular mass, in the previously prepared axis.

Important :

The self-compressing facet screw brings the facet joints closer together around the **FFX** cage, which increases its primary anchorage and promotes bone fusion.



Facet screw

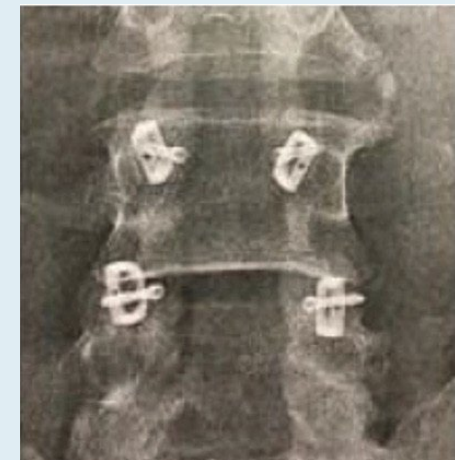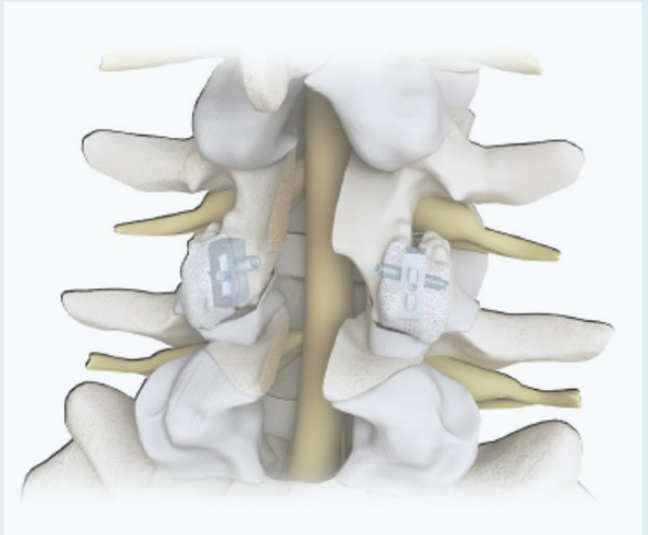


Screwdriver

15. Grafting and closure

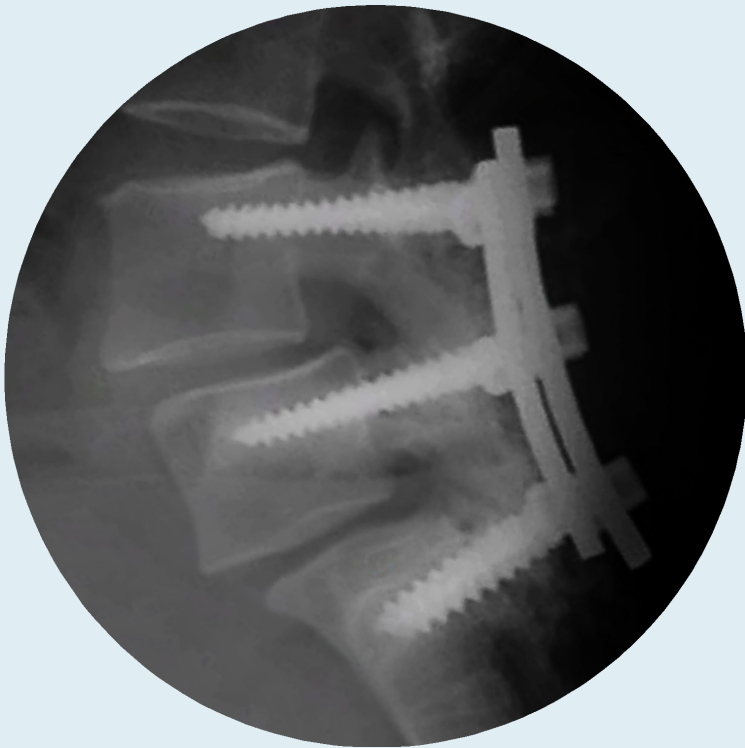Add autologous graft material posterior to the **FFX** cage.

Close according to the usual technique.

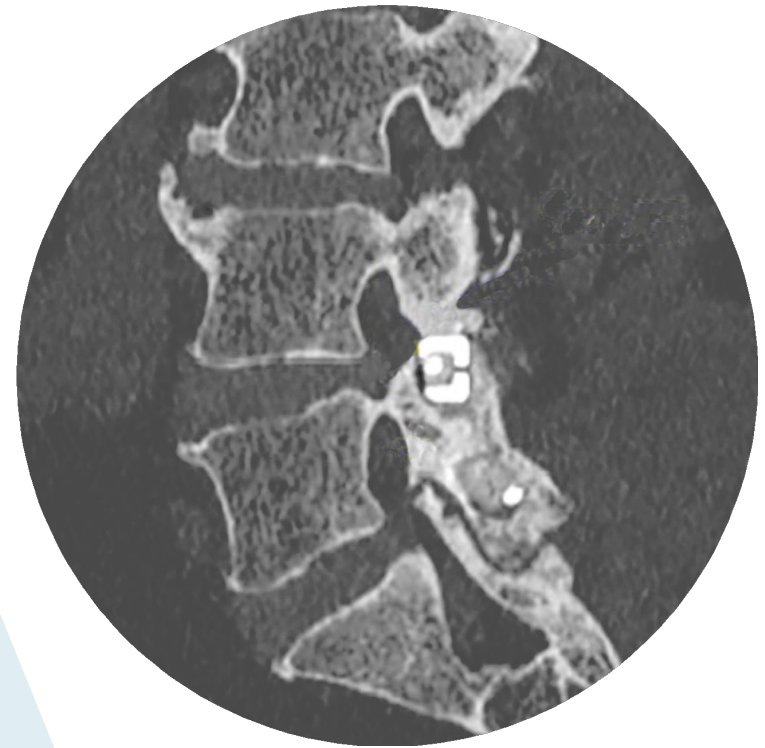



Surgical Results

- ▶ Less invasive
- ▶ Less hardware
- ▶ Unique procedural technique



Pedicle screws



FFX®